

# Early Complications after Pacemaker Implantations

Kabayadondo Maidei Gugu and de Meester Antoine  
*Jolimont Hospital*  
*Belgium*

## 1. Introduction

The clinical benefit of cardiac pacemakers has been long proven through numerous studies. Millions of pacemakers have been implanted worldwide and, as a result the quality of life for these patients has been drastically improved, not forgetting the reduced morbidity and mortality. The first stimulations through transthoracic electrodes were pioneered by Zoll in the early fifties (Zoll, 1952)), then came percutaneous endocardial pacing in 1959 (Furman & Schwedel, 1959).. A “permanent” pacemaker using epicardial electrodes was first described in 1960 (Chardack, 1960). Pacemakers and implantation techniques have progressed rapidly since the then; Generators are more reliable, more compact, filled with micro-electronic components, can be controlled automatically and remotely and thus providing more options for programming and monitoring and a longer pacemaker life span (Kusomoto & Goldschlager, 1996; Trohman, et al, 2004). Leads are thinner and more resistant to damage and thus equally longer-lasting.

The latest European guidelines published in 2007 confirmed the classic indications; symptomatic bradyarrhythmias including sinus node dysfunction and atrioventricular or intraventricular conduction disturbances (Vardas et al., 2007). The guidelines also recommended cardiac pacing for specific conditions (vasovagal syncope, hypertrophic cardiomyopathy, heart failure with prolonged QRS duration, etc). Since over 10 years, left ventricular resynchronisation therapy has proved to be beneficial to patients presenting heart failure with complete left bundle block in association with optimal medical treatment; the European guidelines were updated for this indication in 2010 (Dickstein,2010)

The correct implantation of a pacemaker is capital for optimal function. A recent trend shows pacemaker implantation can be performed as successfully in the electrophysiology study environment as in the operating room (Garcia-Bolao & Alegria, 1999). This requires a centre with a qualified team of cardiologists as well as experienced nursing and technical staff. Continued education for the team and follow-up of complications is essential. The cardiologists’ or surgeons’ experience, and the volume of pacemakers implanted in the centre, plays a role in reducing post-implantation complications; thus, guidelines discourage this procedure in centres with a low volume of implantation.

Despite these precautions, some early complications, occurring within the first 6 weeks after implantation, may be observed. Their incidence is probably underestimated (approximately 7%), as is their severity (Kiviniemi et al., 1999; Klug et al., 2003). Less than 5% have to incur reintervention. Per-procedure mortality is extremely rare; only one case was observed in the cohort of 650 patients implanted at Columbia-Presbyterian Medical Centre. The dutch

database FLOWPACE PM has indexed/listed six variables associated with at least one complication prior to hospital discharge; a low body mass index, history of heart failure (one of the principal indications for implantation), a subclavian venous access, an active fixation auricular pacing lead, and double lead implantation. These patients should be considered at risk for complications (van Eck et al., 2007).

## 2. Clinical cases

Early complications of pacemaker implantation are not uncommon, even in an experienced team of cardiologists or surgeons. Before discharge, careful evaluation of the pacing system is required. Diagnosis of malfunction is not always evident. Most of the patients needed an invasive procedure or medical intervention to prevent further morbidity.

Through practical clinical examples, we aim to elaborate the principal complications of electronic implanted cardiac devices, as well as discuss situations in which the presence of such a device needs to be kept in mind for the work-up of disorders that may or may not seem pacemaker-related.

### 2.1 Case 1 - Iatrogenic pneumothorax resulting from subclavian puncture

A 61 year old man presents to his general practitioner with right thoracic pain and dyspnoea, progressively worsening since three days. He was discharged from cardiology a week before, for implantation of a double chamber pacemaker for sick sinus syndrome with symptomatic atrial fibrillation and bradycardia. Clinical examination revealed good cicatrisation of the implantation site, normal cardiac sounds with no murmur, but abolished respiratory sounds in the right lung. Twelve-lead electrocardiogram (EKG) showed a sinus rhythm with paced ventricular response (typical left bundle block pattern). Chest X-ray confirmed the presence of a complete right pneumothorax (Figure 1). The patient was therefore treated with a chest tube and his recovery was uneventful. The additional hospital stay was three days.

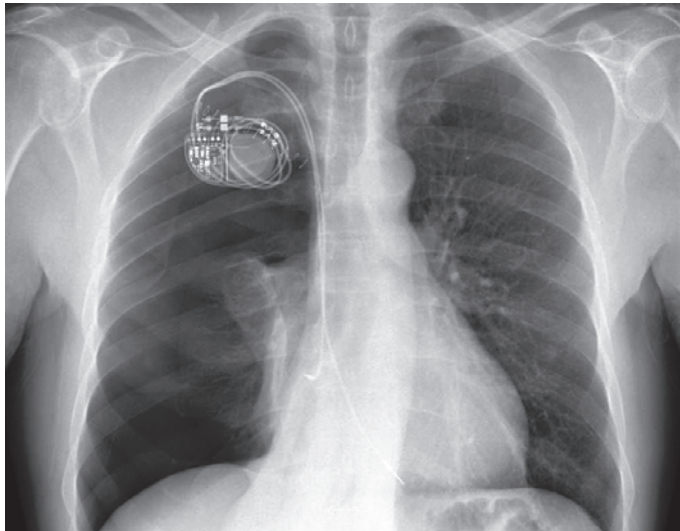


Fig. 1. Chest X-ray showing complete right pneumothorax, which was treated with a chest tube.

**Comments:** Iatrogenic pneumothorax after subclavian venous access is a rare complication whose incidence varies from 1-5% depending on the series, on the realisation of routine post-procedural chest X-ray and on the exact definition of this complication (consideration of both complete and partial pneumothorax, the need for chest tube insertion, hemothorax or gas embolism) (Res et al., 2004). It is usually an immediate complication and is rarely witnessed after discharge. To avoid this complication, access through a central cephalic vein is possible. However, this technique is subject to failure in approximately 20%. The operator's anatomical knowledge and experience reduce this risk. Pneumothorax is usually asymptomatic and resolves spontaneously in most cases. It is to be suspected in all patients presenting with dyspnoea, unexplainably low blood pressure and variable or elevated stimulation thresholds. Chest tube placement with aspiration is necessary if pneumothorax exceeds 10% of lung volume, if tension pneumothorax or hemothorax are diagnosed.

## 2.2 Case 2 - Skin necrosis, suture line failure, and lead erosion due to a large pocket hematoma

An 80 year old male needed pacing for complete atrioventricular block is re-admitted three months after implantation. Despite daily wound care by a home-based nurse, the suture line at the site of implantation would not cicatrize. Patient history included myocardial infarction for which percutaneous cardiac intervention (PCI) with a bare metal stent was performed, as well as receiving classical medical treatment that included clopidogrel and aspirin on a daily basis. After implantation, a large hematoma formed in the generator pocket. A conservative treatment was initially proposed. On re-admission, the hematoma had almost completely disappeared, but severe skin necrosis was impeding site closure to the extent that the leads were visible with the naked eye. The absence of infection, as proved by numerous negative swab cultures, allowed for the pacemaker generator to be re-implanted under the pectoralis muscle.

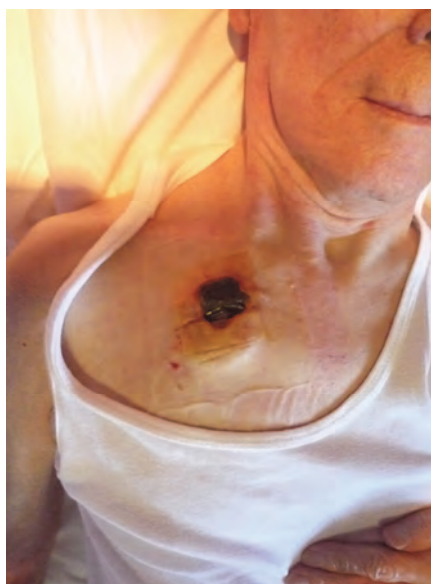

Fig. 2. Hematoma. Lack of suture line healing, pacemaker leads visible.

**Comments:** Pocket hematoma is the most frequent complication (5% of cases) and can lead to prolonged hospital stay and in the latter case, re-implantation (1-2%) (Kiviniemi et al., 1999 ; Wiegand et al., 2004). Risk factors include use of high doses of low molecular weight heparin, of the association aspirin-clopidogrel, and inexperienced operator. Aspirin alone or an oral anticoagulant like warfarin, to take international normalized ratio (INR) of  $< 2.0$ , does not increase the risk of hematoma. Electrocautery or a second look to the pocket is useful to minimize bleeding and the risk of large hematoma. Selective use of topical thrombin is reserved for high risk patients; in Reynolds's series, the incidence of significant hematoma dropped from 20.8% to 8%. Sometimes drain placement may be necessary and sufficient. Evacuation of hematoma is realised in less than 0.5% with a major risk of infection; potential reasons include persistent bleeding, pain refractory to analgesics, failed healing and skin necrosis.

### 2.3 Case 3 - Recurrent syncope due to lead displacement

A 60 year old female patient with no medical history and under no current treatment was admitted for complete atrioventricular block causing shortness of breath and dizziness. Implantation of a double chamber pacemaker was performed with ease. P/R sensings were measured at 3.1 mV and 7.8 mV respectively, and both thresholds for stimulation are 0.5 volt/0.4 msec. The next day, the patient represented with dizziness and faints. Lead displacement was suspected. EKG no longer showed physiological stimulation and chest X-ray confirmed lead displacement (Figure 3). Lead repositioning and active fixation was performed successfully.

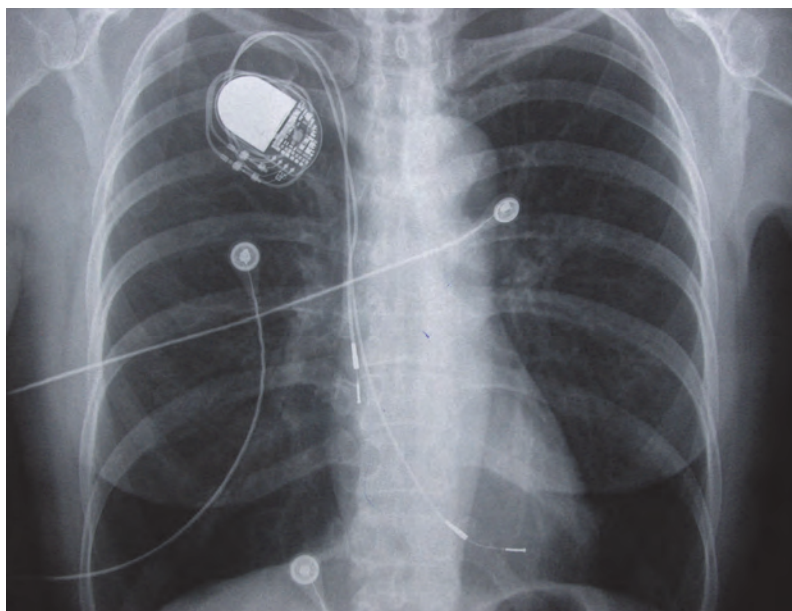


Fig. 3. Chest X-ray showing migration of both atrial and ventricular leads.

<ul style="list-style-type: none"> <li>• Failure to OUTPUT: no pacemaker activity. NO SPIKE <ul style="list-style-type: none"> <li>• battery failure or EOL (end of life), battery trauma</li> <li>• lead problems : lead fracture, lead dislodgement, fractured lead insulation, poor lead connection</li> <li>• oversensing causes (myopotentials, electromagnetic interference, cross-talk phenomenon)</li> <li>• "cross-talk" phenomenon</li> <li>• extreme electromagnetic interference</li> <li>• pseudo-malfunction : hystérésis, normal algorithmes (AV conduction)</li> </ul> </li> </ul>
<ul style="list-style-type: none"> <li>• Failure to CAPTURE: no depolarisation of the cavity. SPIKE without P/QRS complexes <ul style="list-style-type: none"> <li>• normal situation : Functional non-capture – output delivered during refractory period</li> <li>• inappropriate programming of the pacemaker (too low safe margin)</li> <li>• lead problems : lead fracture, lead dislodgement, fractured lead insulation, poor lead connection</li> <li>• myocardial perforation</li> <li>• elevated pacing threshold : <ul style="list-style-type: none"> <li>○ myocardial infarction (necrosis) at the lead tip</li> <li>○ drugs (eg, flecainide)</li> <li>○ dyskaliemia</li> <li>○ metabolic abnormalities (eg, acidosis, alkalosis)</li> </ul> </li> </ul> </li> </ul>
<ul style="list-style-type: none"> <li>• Oversensing (Oversensing occurs when a pacemaker incorrectly senses cardiac/noncardiac electrical activity and is inhibited from pacing): <ul style="list-style-type: none"> <li>• Myopotentials or muscular activity (particularly the diaphragm or pectoralis muscles)</li> <li>• cross-talk phenomenon</li> <li>• electromagnetic interference (eg, Magnetic Resonance Imaging (MRI))</li> <li>• lead fracture and fractured lead insulation</li> </ul> </li> </ul>
<ul style="list-style-type: none"> <li>• Undersensing (Undersensing occurs when a pacemaker incorrectly misses intrinsic depolarization and paces despite intrinsic activity) <ul style="list-style-type: none"> <li>• Normal device function – misinterpretation : triggered mode, fusion and pseudo-fusion beats, functional undersensing (long refractory periods, blanking period, safety pacing, oversensing)</li> <li>• poor lead positioning (poor intrinsic signal amplitude), lead dislodgment, lead fibrosis or thrombosis</li> <li>• magnet application</li> <li>• battery depletion</li> <li>• drugs (eg, flecainide, amiodarone)</li> <li>• metabolic abnormalities (eg, acidosis, alkalosis)</li> <li>• dyskaliemia (eg, hyperkaliemia)</li> <li>• hypothyroidism</li> <li>• ischemia and myocardial infarction</li> <li>• or electrical shock (transient)</li> </ul> </li> </ul>

Table I. Pacemaker Troubleshooting and early complications of pacemaker insertions

**Comments:** Lead displacement can be found in 2-10% of cases depending on the series (Kiviniemi et al., 1999 ; van Eck et al., 2007). Atrial leads migrate more often than ventricular leads. Active fixation reduces the risk, especially in patients having undergone cardiac surgery. Manifestations include undersensing, failure to capture and increase in pacing thresholds. Repositioning of leads is primordial. Causes of undersensing include lead displacement, fibrosis at the site of fixation of the lead, myocardial ischemia and necrosis, some antiarrhythmic agents (flecainide), dyskaliemia, or transient undersensing following an electric shock (Table I) (de Meester, 2008). When lead displacement is induced by the patient, following a repetitive rotational movement (twisting of the box) and leading to winding of the leads around the generator, we talk of Twiddler's syndrome; this is observed in certain psychiatric cases, or when the pocket is too big for the pacemaker generator.

#### 2.4 Case 4 - Minor right ventricular perforation

A 77 year-old patient had a physiological pacemaker implanted for symptomatic sinus bradycardia, with sinus arrest. A few days after the intervention, she presented with continuous chest pain. Upon clinical examination, blood pressure was 130/80 mmHg, heart sounds were regular but a pericardial friction rub was audible. EKG showed a sinus rhythm with ventricular capture. Chest X-ray revealed a ventricular lead projecting further than the apex (Figure 4). Cardiac ultrasounds confirmed myocardial perforation by the lead and a minimal pericardial effusion. We decided to abstain from removing the lead, which would have been to some extent invasive in this elderly patient. Treatment by anti-inflammatory drug was installed and was sufficient for pain relief.

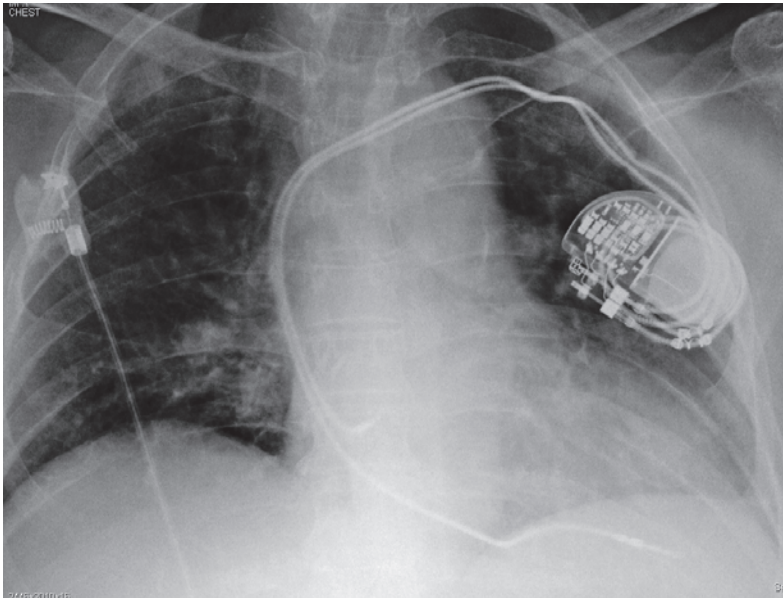


Fig. 4. Chest X-ray showing atrial and ventricular leads, with the ventricular lead clearly beyond the cardiac shadow

**Comments:** Cardiac perforation is a serious complication, with risk of tamponade and death. It occurs in less than 2% of cases (Ellenbogen et al., 2002). Clinical symptoms are variable, including chest pain, shortness of breath and more rarely hypotension and shock. Advanced age, use of active fixation leads and operator inexperience are contributing factors (Mahapatra et al., 2005). Furthermore, atrial leads seem to perforate more frequently (Hirschl et al., 2007). The new Magnetic Resonance Imaging (MRI)-compatible leads are more rigid, but increased frequency of perforation does not seem to be induced by the use of these leads. Treatment is not standardised, but removal (and replacement) of these leads is crucial in the case of tamponade and shock. Pericarditis without perforation has been observed in 5% of cases and must lead to close follow-up. Figure 5 illustrates a case of tamponnade. The patient remained stable after drainage.

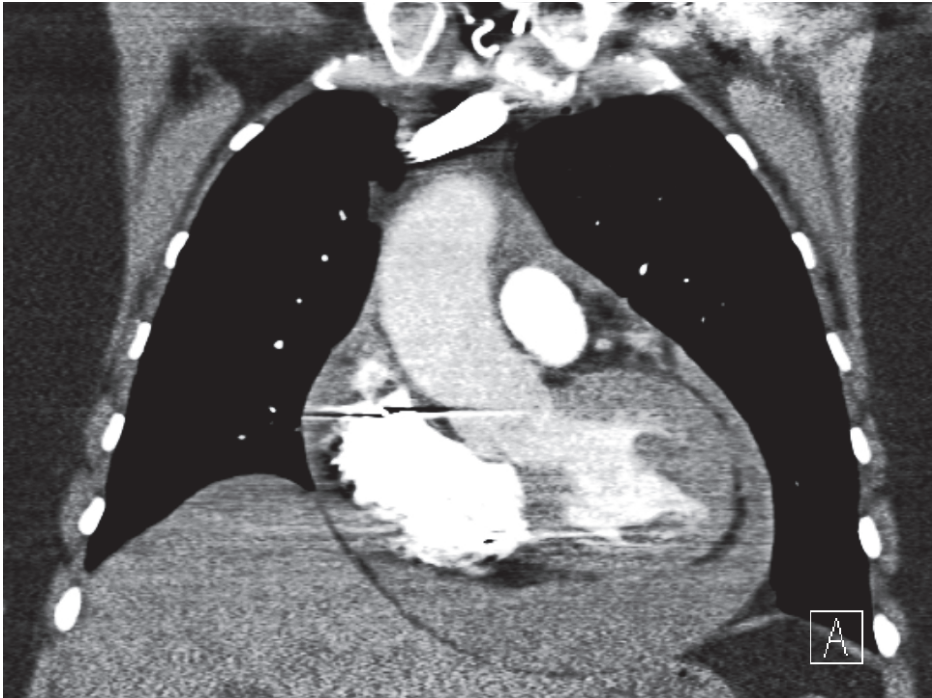


Fig. 5. Chest scan showing significant pericardial effusion, responsible for pre-tamponnade and shock.

### 2.5 Case 5 - Skin erosion and exterisation of the generator

An 85 year old female patient is admitted for malaise and confusion. Medical history is positive for asthma treated regularly by corticoids and B2 mimetic aerosols. EKG shows a complete atrioventricular block and, after excluding all reversible causes, a physiological pacemaker is implanted. No complications are noted during her hospital stay. Having regained her autonomy and the confusional episode resolved, the patient returns to her old age home with instructions for routine care for the following weeks. A follow-up is programmed at six weeks and the cardiologist is confronted with a case of skin erosion and

exteriorisation of the pacemaker generator (Figure 6). Due to the high risk of infection in this case, the device is removed and a new device is implanted on the contra-lateral side after six weeks of antibiotherapy and with negative hemocultures.

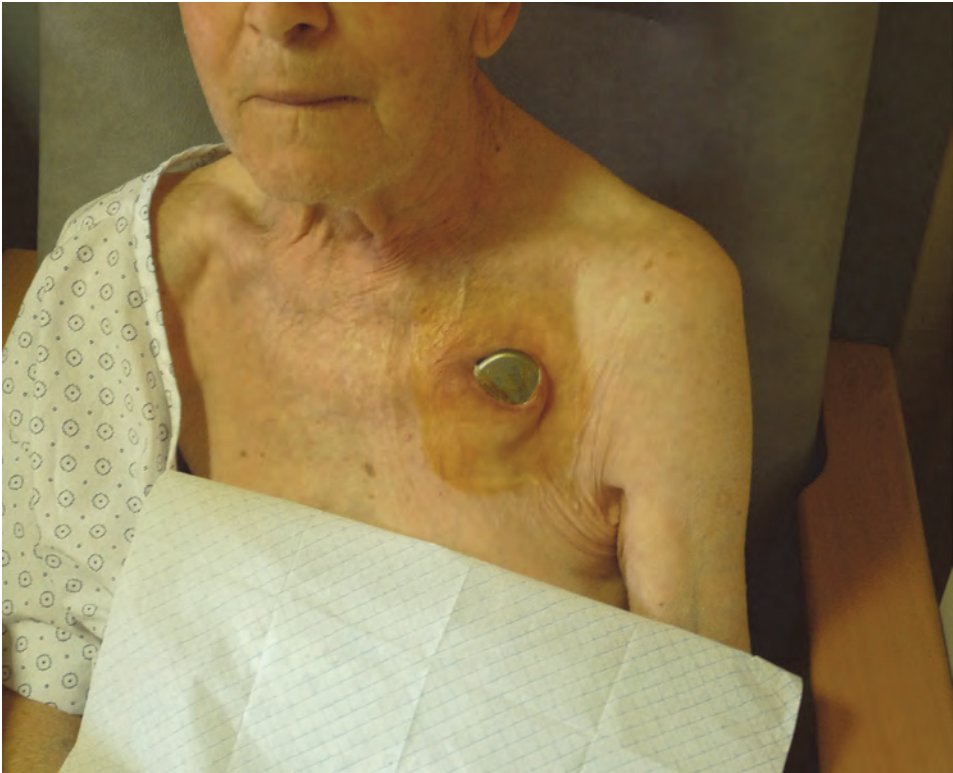

Fig. 6. Erosion and exteriorisation of pacemaker generator in our elderly patient.

**Comments:** Skin erosion is caused by the pacemaker generator, and is usually a result of pocket infection. Other precipitating factors can be present, for example, the extremely fragile skin of elderly patients, a pocket that is too small, precarious subcutaneous fat, chronic use of corticoids, and use of abrasive disinfectants (Kiviniemi et al., 1999). Exteriorisation of a generator, and/or a lead, is always associated with bacterial contamination, making removal of the material an obligation, accompanied by antibiotherapy and eventually re-implantation on the contra-lateral side. Skin erosion is hence to be sort for and detected before exteriorisation. This is rarely an early complication, and incidence is estimated to be 1%.

### **2.6 Case 6 - Ventricular lead malposition and right bundle branch block morphology on EKG**

A 55 year old patient with history of hypertension, obesity, diabetes, anterior myocardial infarction and severe left ventricular dysfunction has a defibrillator implanted in primary prevention of sudden death. The follow-up is satisfactory with acceptable sensing, impedance



and threshold stimulation values on the device programmer. EKG shows a sinus rhythm with evident old anterior infarction. Chest X-ray, performed in a recumbent position and under non-optimal condition seems satisfactory and the patient is discharged. Upon follow-up one month later, the parameters of the defibrillator are still satisfactory, but the ventricular stimulation shows atypical right bundle block. Chest X-ray confirms the suspected left ventricular stimulation, via a permeable foramen ovale (Figure 7). Lead replacement is indicated seeing the high risk of thrombo-embolic complications in this young patient.

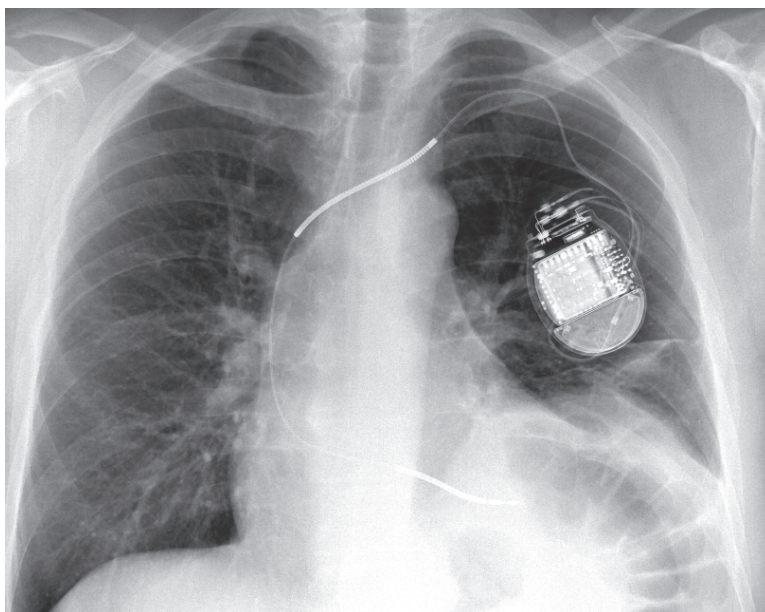


Fig. 7. Chest X-ray showing a ventricular lead that is located higher than usual; this lead is in the left ventricle, having gone through a patent foramen ovale.

**Comments:** an erroneous lead placement is extremely rare. It remains possible in patients with a patent foramen ovale or an atrial septal defect. Less than twenty cases are reported in the literature (Allie et al, 2000; Blommaert et al., 2000 ; Van Gelder al, 2000; Le Dolley et al, 2009). An EKG during stimulation and chest X-ray in an upright position (antero-posterior and lateral takes) are recommended. The risk of thrombo-embolism, including stroke, of mitral insufficiency should be evaluated. Repositioning of the lead or long term anticoagulation should be considered. When right bundle branch block pacing morphology appears in a patient with a permanent or temporary transvenous right ventricular pacemaker, myocardial perforation or malposition of the pacing lead must be ruled out, even though the patient may be asymptomatic. The overall causes of right bundle branch block morphology include:

- erroneous left ventricular lead placement in patient with an atrial septal defect
- biventricular stimulation or cardiac resynchronisation therapy (CRT) (Figure 8)
- epicardial lead placement.
- some cases of "normal" right ventricular apical stimulation

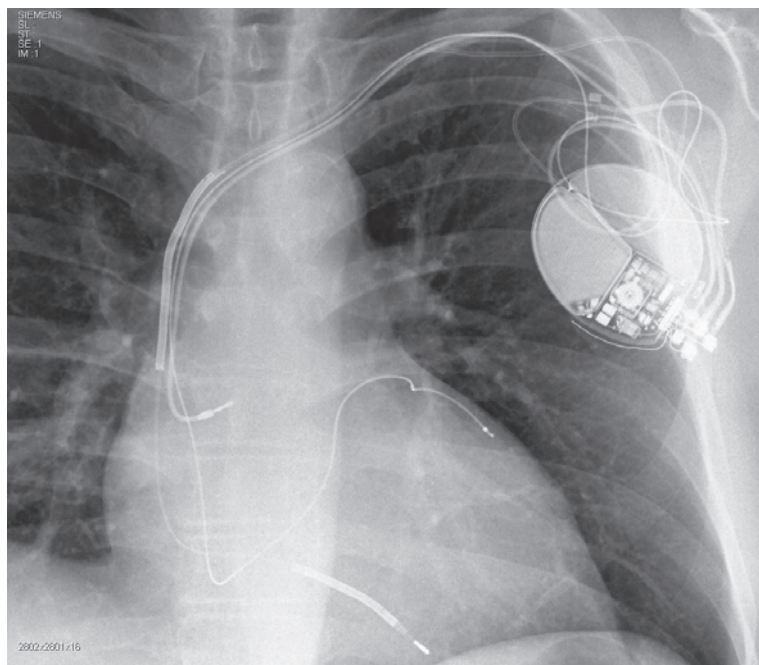


Fig. 8. Chest X-ray showing implantation of 3 leads including a left ventricular lead placed in a branch of the coronary sinus (cardiac resynchronisation therapy).

### 2.7 Case 7 - Twiddler syndrome in a psychiatric patient

A 68 year old patient, with a history of chronic obstructive pulmonary disease and psychosis, underwent pacemaker implantation for repeated loss of consciousness due to sinus hypersensitivity. Carotid sinus massage resulted in 10 second pauses. The pacemaker was set in double chamber mode and after satisfactory programming control (P-R sensing 2.5 mV and 12.5 mV, impedance at 564 ohms and 496 ohms respectively, stimulation thresholds at 0.5 volts/0.4 msec), the patient was discharged to his psychiatric institution. At one month follow-up, the patient has no complaints, though anamnesis is laborious. Check-up of the stimulator shows absence of detection of both P and R waves, and absence of atrioventricular capture despite maximal stimulation. Displaced leads are suspected and confirmed by chest x-ray (Figure 9). The patient later admits to having manipulated the pace generator by repeatedly twisting it around. Correct repositioning and fixation of the leads were conducted.

**Comments:** Twiddler's syndrome is describes as the migration of cardiac stimulator leads due to repetitive rotatory movements of the generator in its pocket, secondary to manipulation by the patient himself, which may be intentional or non-intentional (for example, sportsmen). In certain cases, the stimulation of displaced leads can cause pectoral muscle contraction, or life-threatening symptoms in the case of pacemaker dependency (Nicholson et al, 2003; Castillo & Cavusoglu, 2006; Essoh et al., 2010) (Figure 10).

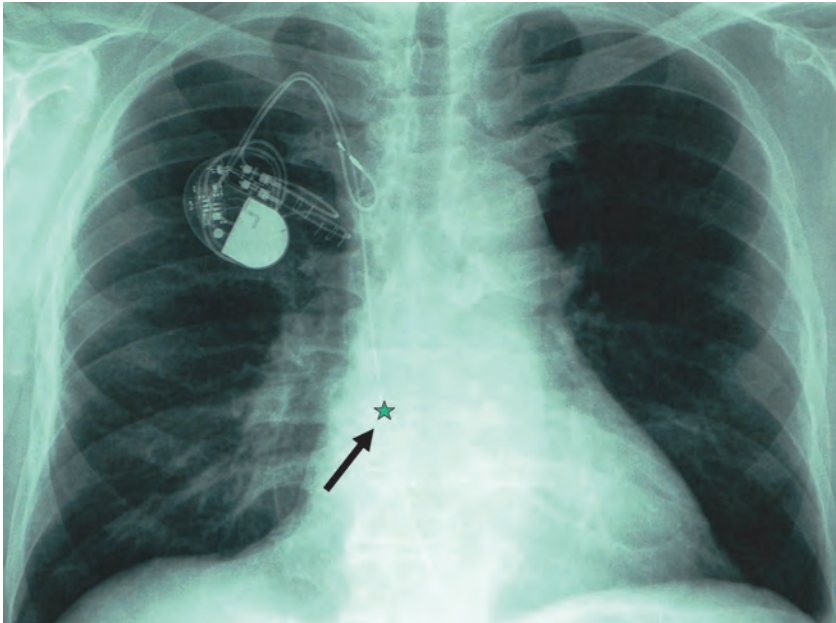


Fig. 9. Chest X-ray showing displaced lead (ventricular lead tip indicated by the star).

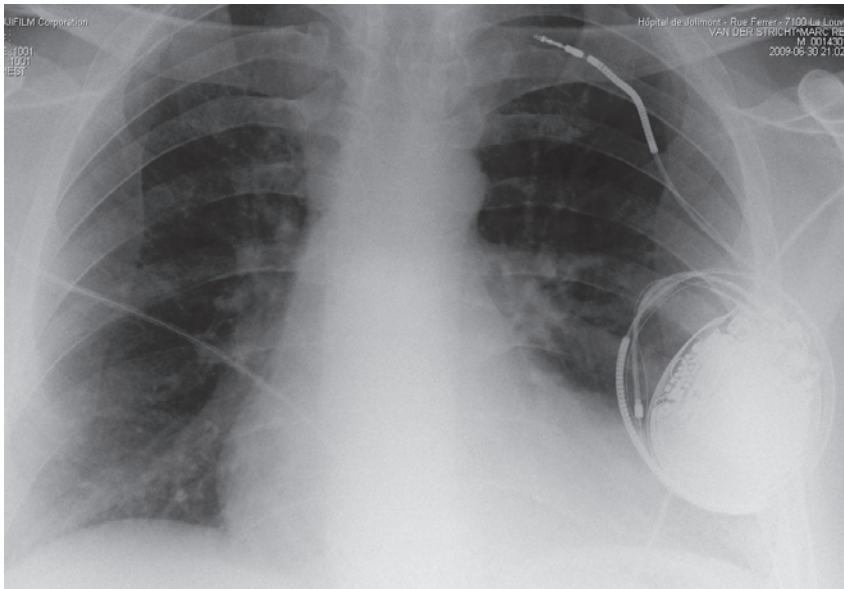


Fig. 10. Chest X-ray showing dual-coil ventricular lead displacement, causing pectoral permanent stimulation, in a case previously reported by our team (Essoh et al, 2010). Repositioning the lead was required and successfully reported.

Risk factors include obesity (adipose tissue being less firm in these patients), female sex, elderly patients, patients known as having stigmata for character disorders (obsessive compulsive tendencies, dementia). Treatment consists of repositioning the leads, and changing them in the event of fracture. Several surgical techniques have been proposed to avoid recurrence; implanting the pacemaker generator under the aponevrosis, active lead fixation (almost always the case with implantable cardioverter-defibrillators), Parsonet's dacron pouches. Patient education, and psychiatric treatment if indicated, should be proposed.

### **2.8 Case 8 - Early venous thrombosis after defibrillator with resynchronisation (CRT-D) placement**

A 73 year old male has a defibrillator with resynchronisation implanted for ischemic cardiomyopathy after an anterior infarction left him with a left ventricular ejection fraction of 25%. He had presented an episode of ventricular tachycardia with syncope. Implantation of the device was by the subclavian route. There were no immediate post-operative complications and good parameters were recorded for all three leads. Three weeks later, the patient complains of discomfort in the left arm, followed by oedema of the whole arm, forearm and hand (Figure 11); ultrasound and vascular tomodensitometry confirmed complete thrombosis of the left subclavian vein, of the axillary vein, leading up until the convergence of the jugular vein. Anticoagulation therapy was commenced and evolution was slow but favourable in the following weeks.

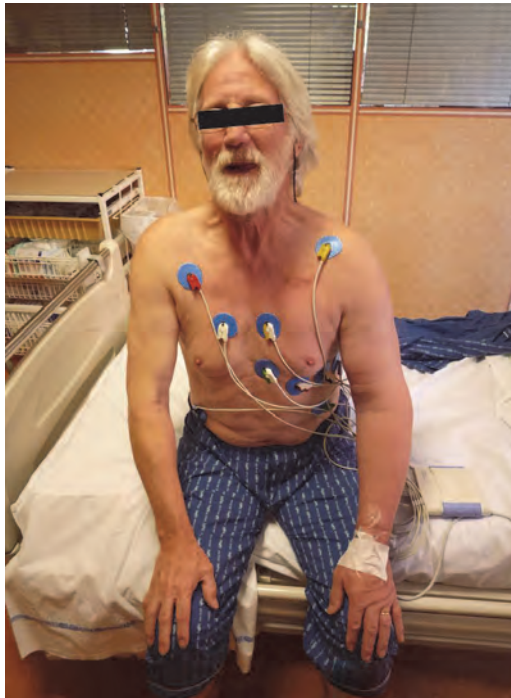

Fig. 11. Oedema of the left arm, forearm and hand caused by massive thrombosis of the subclavian vein after defibrillator with Cardiac Resynchronisation Therapy (CRT-D).

**Comments:** Subclavian vein thrombosis is not uncommon. It can occur in about 30% of cases, but usually remains asymptomatic due to the rapid development of collateral circulation (Oginosawa et al., 2002). Less than 5% of patients are symptomatic, presenting mainly with pain or oedema of the arm closest to the implantation site. Risk is higher in cases where three leads are implanted (Cardiac Resynchronisation Therapy (CRT), when the patient is under hormonal therapy, when personal history of thrombo-embolic event is present, with temporary ipsilatérale transvenous lead, during upgrade of a simple pacemaker to a pacemaker with resynchronisation, dual coil leads, and when the ejection fraction is less than or equal to 40% (Da Costa et al., 2003 ; Rozmus et al., 2005). The risk of thrombosis does not differ for pacemakers and implantable cardioverter-defibrillators. Preventive measures may be necessary (platelet aggregation inhibiting drugs or anticoagulation therapy).

### 2.9 Case 9 - Unusual tachycardia after implantation of a double-chamber pacemaker

A 75 year old male is admitted for repeated fainting caused by major sinus dysfunction as shown by a 24 hour Holter monitor which revealed pauses of up to 8 seconds and paroxysmic atrial fibrillation. Medical history was negative and patient was on no current treatment. EKG at rest showed a sinus rhythm with a frequency of 68 bpm and normal repolarisation. A physiological pacemaker is implanted in the operating room. After the intervention, the patient feels palpitations and an EKG recording shows probable pacemaker-mediated tachycardia (Figure 12). Programming control shows a P-R sensing of 15.8 mV and 1.2 mV respectively, and threshold values for stimulation both inferior to 0.5 volts for 0.4 msec; a connection error is confirmed during threshold verification. Programming in AAI mode would result in VVI pacing, and programming in VVI mode would result in AAI pacing. Re-intervention allowed the correction of this connection error.

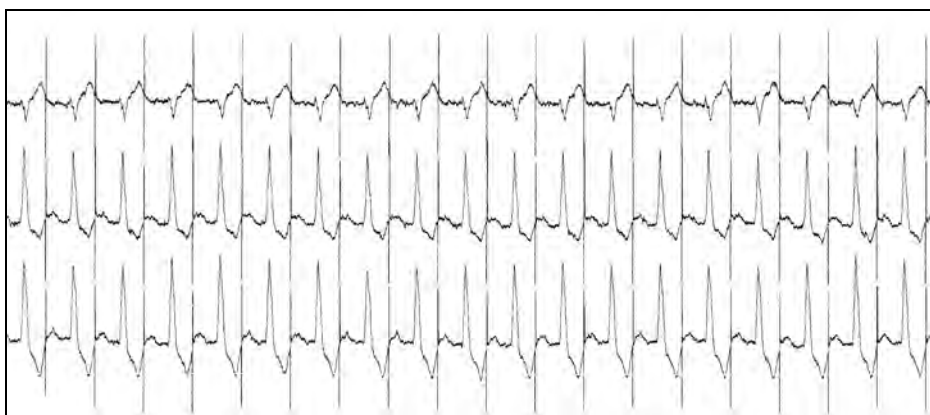

Fig. 12. Tachycardia due to an error in the connection of the atrial and ventricular leads. We note the same QRS configuration as with VVI pacing from the apex.

**Comments:** Atrial and ventricular lead connection errors are rare at implantation, but have already been documented (Barold et al, 2010). Programming verification allows rapid detection of the switch (“green wire on the green button and red wire on the red button”). A control of the programming of a stimulator is mandatory before patient discharge. It

allows detection and correction of such an error, as well as early detection of a lead displacement. Different types of tachycardia are to be excluded:

- Classical "endless loop" or pacemaker mediated tachycardia is rare with the double chamber generators of today.
  - it is usually initiated by an extra-systole with a retrograde p wave which is easily detected and sustains the circuit. Pacemaker mediated tachycardia can also be provoked by ventricular extra-systoles, by atrial over-detection (myopotentials, interferences) or underdetection and failure to capture
  - long post-ventricular atrial refractory period (PVARP), excluding retrograde P wave and retrograde conduction, may prevent pacemaker mediated tachycardia
- Runaway Pacemaker is due to a malfunction of the pacemaker generator resulting in life-threatening rapid tachycardia (up to 200 bpm).
  - the generator may malfunction for various causes, including battery failure or external damage.
  - the use of a magnet can reduce the rate of the rhythm induced by the defiant pacemaker. Generator replacement is necessary.
- Atrioventricular nodal reentrant tachycardia. In this case, the stimulator does not intervene in the circuit.
  - figure 13 shows the initiation of the common type (slow-fast) of atrioventricular nodal reentrant tachycardia ; this is a typical example where the arrhythmia is triggered by an atrial extrasystole which blocks the rapid pathway of the atrioventricular node and allows flow through the slow pathway and thus initiation of the supraventricular tachycardia circuit
  - radiofrequency ablation is the treatment of choice.
- Other reentrant tachycardia includes
  - atrial flutter
  - orthodromic circus movement tachycardia using an accessory pathway in the retrograde direction and the AV node in the anterograde direction (concealed or not, in the Wolff-Parkinson-White syndrome)
  - atrial tachycardia (paroxysmal and nonparoxysmal)

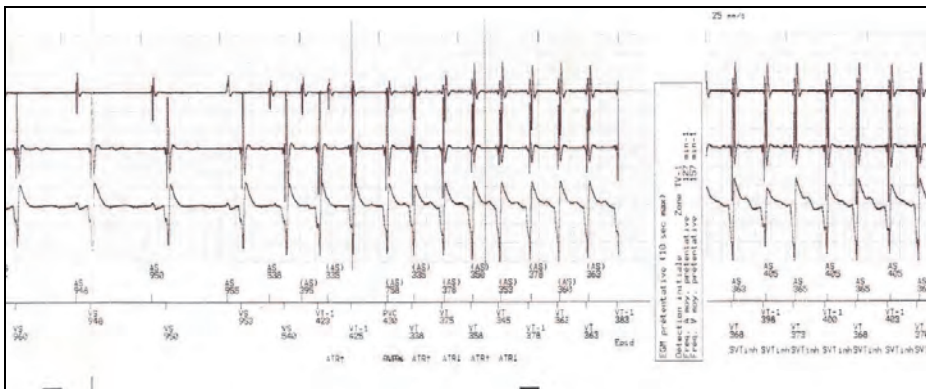


Fig. 13. Baseline rhythm strip showing atrial, ventricular and shock intracardiac electrogram leads, and marker atrial and ventricular channels. This is an example of initiation of common atrioventricular node reentrant tachycardia; see text.

### 2.10 Case 10 - Recurrent malaise after pacemaker implantation

A man aged 65 with history positive for high blood pressure, diabetes and renal failure actually undergoing haemodialysis receives a pacemaker for complete atrioventricular block with syncope. His treatment includes ramipril, aspirin and insulin. No immediate post-operative complications occur. Just before a haemodialysis session a few days later, the patient complains of feeling faint. An EKG shows evident signs of hyperkalemia (very wide QRS complexes with tall peaked T waves and obliteration of the ST segment, as well as a long PR interval) and of double chamber stimulation without atrial or ventricular captures (Figure 14). Blood work-up confirms severe hyperkalemia (potassium 7.8 mEq/L). The atrioventricular underdetection and the absence of capture are caused by the high level of potassium and corrected as soon as kaliemia is normalised by haemodialysis.

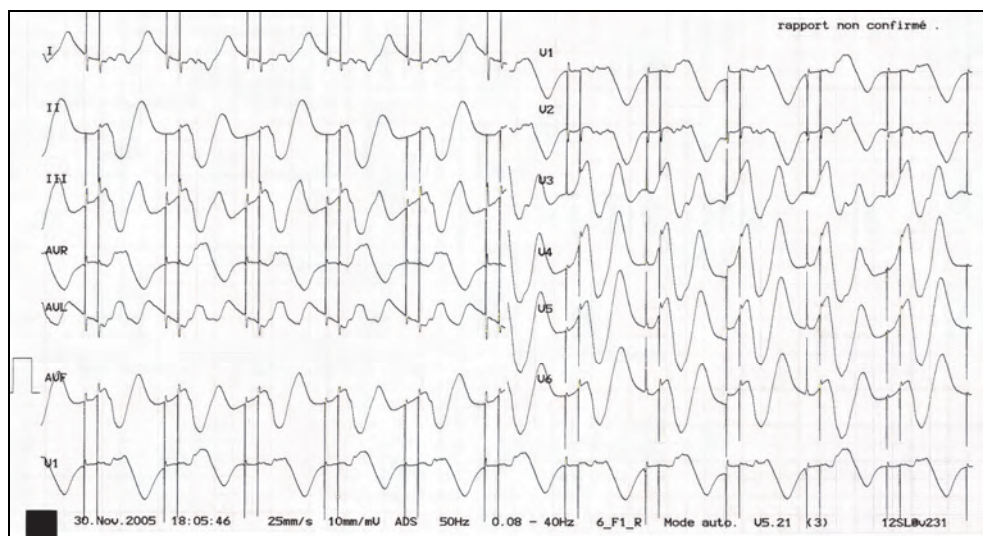


Fig. 14. Twelve-lead EKG showing signs of hyperkalemia and defiant AV detection and stimulation.

**Comments:** Causes of atrioventricular underdetection and failure to capture are shown in table I. Hypokalemia is another cause of life-threatening undersensing (de Meester et al, 1996). Correction of the cause is essential for adequate pacemaker function. The risk of triggering ventricular fibrillation, due to a ventricular stimulation during the vulnerable T wave period (R-on-T phenomenon), is present, as is present in asynchronous VOO stimulation or the use of a magnet (Oupadia et al., 1998).

### 2.11 Case 11 - Important dyspnoea and malaise at follow-up

A 68 year old patient was admitted for class III dyspnoea according to the New York Heart Association (NYHA) score and repeated episodes of malaise since implantation of a single chamber pacemaker in another centre. Her personal history is positive for hypertension and sick sinus syndrome with atrial fibrillation associated with a slow ventricular rhythm and pauses of more than 8 seconds, hence the indication for cardiac pacing. Her treatment is comprised of ramipril, amlodipin and an oral anticoagulant, (acenocoumarol). Clinical

examination is unremarkable. Blood pressure was 130/80 mmHg. Twelve-lead EKG shows regular ventricular stimulation at 70 beats per minute, and a basal sinus rhythm. Dissociated P waves are seen (Figure 15). Pacemaker syndrome is suspected, and confirmed. The pacemaker was reprogrammed to VVI 30 bpm to avoid deleterious ventricular stimulation in this patient.

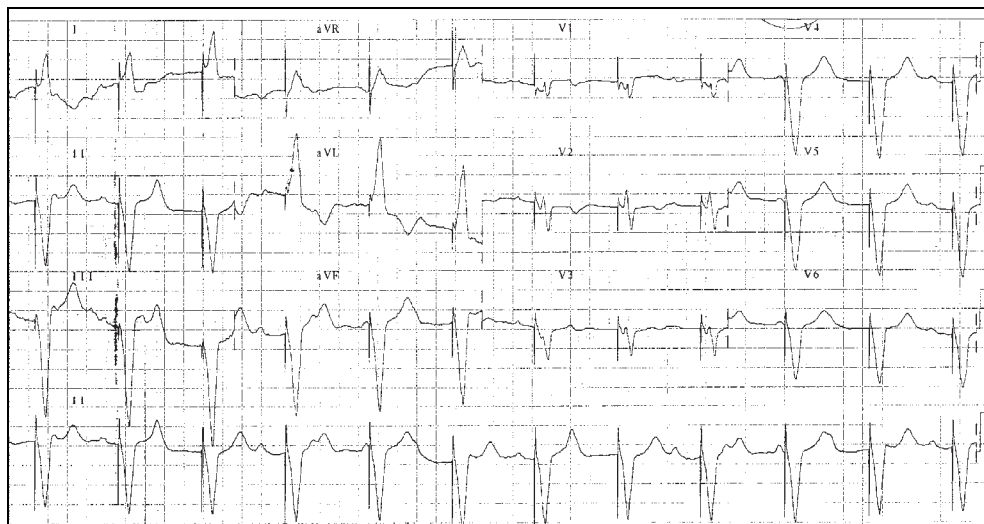


Fig. 15. Twelve-lead EKG showing a dissociated sinus rhythm with right ventricular stimulation.

**Comments:** This is not a veritable implantation complication but the erroneous choice of a single chamber pacemaker whereas a physiological (or double chamber) stimulator would have avoided the problem. Pacemaker syndrome is described as a combination of symptoms evoking cardiac failure and hypotension in a patient with a cardiac stimulator (Chalvidan et al., 2000). It is caused by the loss of atrioventricular synchronism leading to a drop in cardiac output, elevated atrial pressure and hypotension. The Mode Selection Trial (MOST) investigators defined pacemaker syndrome as occurring if either one of two different criteria occurred (Link et al., 2004). The first criterion was new or worsened dyspnea, orthopnea, elevated jugular venous pressure, rales, and oedema with ventricular (VA) conduction during ventricular pacing. The second criterion was symptoms of dizziness, weakness, presyncope, or syncope, and a >20 mmHg reduction of systolic blood pressure when the patient had VVIR pacing compared with atrial pacing or sinus rhythm. Its incidence is 7-20% of stimulators in VVI mode with a sinus rhythm. Pacemaker syndrome can also be seen in AAIR mode and in double chamber modes (VDD, DDI, DDD) if the stimulator if programming is sub-optimal or the stimulation mode is incorrectly selected. Dyspnoea should, besides pacemaker syndrome, evoke:

- chronotrope insufficiency, especially during exertion, requiring programming in rate-responsive mode.
- Wenckebach functioning in DDD mode
- intermittent dysfunction (sensing and pacing)



### 2.12 Case 12 - Acute infection of the pocket and the cardiac device

A 45 year old female patient suffering from idiopathic congestive cardiomyopathy with a left ventricular ejection fraction of 35%, class III dyspnoea on the New York Heart Association (NYHA) scale, left bundle branch block morphology, with a QRS duration of 175 msec, on EKG and under optimal medical treatment for over three months receives a pacemaker with left ventricular resynchronisation. Implantation was complicated immediately by left ventricular lead displacement. A Starfix Attain OTW 4194 (Medtronic Inc., Minneapolis, MN, USA) was necessary for stability (The Attain Starfix's design includes three soft, polyurethane lobes near the lead tip that, when expanded, enable stable lead placement in the target location) (de Meester, 2010). After one month, the implantation site becomes suppurative (Figure 16). Local wound care and 10 day antibiotherapy did not help. Bacteriological studies revealed the presence of *pseudomonas aeruginosa*. Treatment required complete ablation of the material and prolonged antibiotherapy. Re-implantation on the counter-lateral side in this case was performed two months after the end of the antibiotic course.

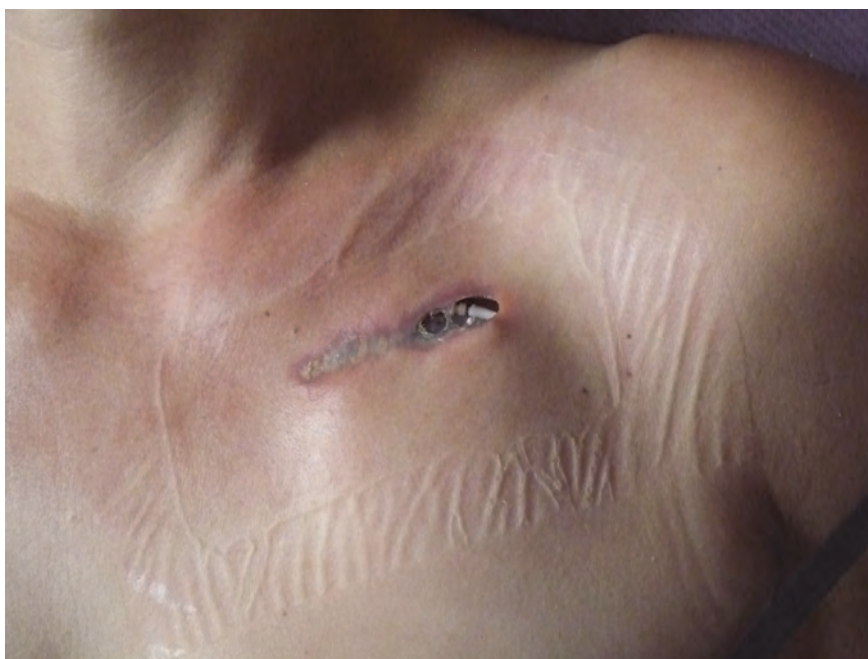

Fig. 16. Photograph showing suppurative wound with visible pacemaker leads. Ablation of all material was necessary.

**Comments:** Suture or pocket infection is not a rarity during the first month and incidence is estimated to be 1% (del Rio et al., 2003 ; Klug et al., 2007). Principal risk factors are re-intervention, diabetes, old age, corticoids, operator inexperience, and renal failure. Antibiotic prophylaxis prior to pacemaker implantation has a protective effect. In the case of very early infection, a per-operative contamination by cutaneous flora (*staphylococcus aureus*) is the principal source of infection (Kearney et al., 1994 ; Da Costa et al., 1998).

Successful treatment of an infected device requires removal of the entire system and administration of antimicrobials. Infection after one month usually originates from the lead (and not the pocket). Sepsis is uncommon and diagnosis includes positive blood cultures (80% of cases) and transesophageal echography showing lead anomalies. Skin erosion at pocket site and other local signs of infection are common. Staphylococcus epidermidis or other gram negative bacteria are most commonly found.

### 3. Conclusions

Early complications after pacemaker and other cardiac device implantation are not uncommon. Hematoma, skin erosion and pocket infection, as well as lead displacement are the most common of these complications and should be looked for and recognised during routine follow-up, as well as during work-up of any patient presenting a new symptom in the first couple of weeks after implantation. Operator inexperience and implantation in a low-volume centre increases the risk of these complications. Adherence to good practice and recommended guidelines is indispensable.

### 4. References

- Allie, DE; Lirtzman, MD; Wyatt, CH; Vitrella, DA; Walker, CM. (2000); Septic paradoxal embolus through a patent ovale after pacemaker implantation. *Ann Thorac Surg*, 69: 946-8.
- Barold, SS; Stroobandt, RX; Sinnaeve, AF. (2010). Cardiac Pacemakers and Resynchronization Step by Step: An Illustrated Guide, *Wiley-Blackwell editors*.
- Blommaert D, Mucumbitsi J, De Roy L. Images in cardiology. Ventricular pacing and right bundle branch block morphology: diagnosis and management. *Heart*. 2000; 83: 666.
- Castillo, R & Cavusoglu, E. (2006). Twiddler's syndrome: an interesting cause of pacemaker failure. *Cardiology*, 105: 119-21.
- Chalvidan, T ; Deharo, JC ; Djiane P. (2000). Les syndromes du pacemaker. *Ann Cardiol Angeol*, 49 : 224-9
- Chardack, WM; Gage, AA; Greatbatch, W. (1960) A transistorized self-contained, implantable pacemaker for the long-term correction of heart block. *Surgery*, 48: 643.
- Da Costa, A; Lelièvre, H; Kirkorian, G et al. (1998). Role of the preaxillary flora in pacemaker infections: a prospective study. *Circulation*, 97: 1791-8.
- Da Costa, SS; Scalabrini Neto, A; Costa, R; Caldas, JG; Martinelli Fihlo, M. (2002); Incidence and risk factors of upper extremity deep vein lseions after permanent transvenous pacemaker implant: a 6-month follow-up prospective study. *Pacing Clin Electrophysiol*, 25: 1301-6.
- del Rio, A; Anguera, I; Miro, JM; Mont L, Fowler VG, Azqueta M, et al. (2003). Surgical treatment of pacemaker and defibrillator leads endocarditis. *Chest*, 121: 1451-9.
- de Meester, A ; Jacques, JM ; Jopart, P ; Chaudron, JM. (1996). Syncope chez une patiente porteuse d'un stimulateur cardiaque. *Louvain Med*, 115: 465-71.
- de Meester, A. (2008). Manuel pratique de cardiologie aiguë. 3<sup>ème</sup> édition. Antoine de Meester éditeur. European Graphics, Strépy-Bracquegnies.
- de Meester, A; van Ruyseveldt, P; Blaimont, M; Prioux, D; Marcovitch; O. (2010). Déplacement de la sonde ventriculaire gauche: existe-t-il une possibilité de remédier à ce problème? *J Cardiol*, 22 : 295-9

- Dickstein, K; Vardas, PE; Auricchio, A et al for the Task Force Members (2010). 2010 focused update of ESC guidelines on device therapy in heart failure. *Eur Heart J*, 31: 2677-87.
- Ellenbogen, K.A.; Wood, M.A. & Shepard, R.K. (2002). Delayed complications following pacemaker implantation. *Pacing Clin Electrophysiol*, 25, 1155-8
- Essoh, E ; Badot, D ; Marcovitch, O ; de Meester, A. (2010). Docteur, j'ai le hoquet à l'épaule! Une cause rare de dysfonctionnement d'un défibrillateur implantable. *Louvain Med*, 129 : 237-40.
- Furman, S; Schwedel, JB. (1959). An intracardiac pacemaker for Stokes-Adams seizures. *N Engl J Med*, 261: 948.
- Garcia-Bolao, I; Alegria, E. (1999). Implantation of 500 consecutive cardiac pacemakers in the electrophysiology laboratory. *Acta Cardiol*, 54: 339
- Hirschl, DA; Jain, VR; Spindola-Franco, H; Gross, JN; Haramati, LB. (2007). Prevalence and characterisation of asymptomatic pacemaker and ICD lead perforation on CT. *Pacing Clin Electrophysiol*, 30: 28-32.
- Kearney, R; Eisen, HJ; Wolf, JE. (1994). Nonvalvular infection of the cardiovascular system. *Ann Intern Med*, 121: 219-30
- Kiviniemi, MS; Pirnes, MA;, Eranen, HJ et al. (1999). Complications related to permanent pacemaker therapy. *Pacing Clin Electrophysiol*, 22: 711
- Klug, D ; Marquie, C ; Lacroix, D ; Kacet, S. (2003). Complications de la stimulation cardiaque définitive. *Arch Mal Cœur*, 96 : 546-53.
- Klug, D; Balde, M; Pavin, D, et al. (2007). Risk factors related to infections of implanted pacemakers and cardioverter-defibrillators: results of a large prospective study. *Circulation*, 116: 1349-56.
- Kusomoto, FM; Goldschlager, N. (1996) Cardiac pacing. *N Engl J Med*, 334: 89-97
- Le Dolley, Y; Thuny, F; Bastard, E; Riberi, A; Tafanelli, L; Renard S, et al. (2009). Pacemaker Lead Vegetation Trapped in Patent Foramen Ovale. *Circulation*, 119: e223-4
- Link, MS; Hellkamp, AS; Estes, NAM, et al. (2004). High incidence of pacemaker syndrome in patients with sinus node dysfunction treated with ventricular-based pacing in the Mode Selection Trial (MOST). *J Am Coll Cardiol*, 43: 2066-71
- Mahapatra, S.; Bybee, K.A.; Bunch, T.J.; Espinosa, R.E.; Sinak, L.J.; McGoon, M.D. & Hayes, D.L. (2005). Incidence and predictors of cardiac perforation after permanent pacemaker placement. *Heart Rhythm*, 2, 907-11
- Nicholson, WJ ; Tuohy, KA ; Tilkemeier, P. (2003). Twiddler's syndrome. *N Eng J Med*, 34: 1726-7.
- Oginosawa, Y; Abe, H; Nakashima, Y. (2002). The incidence and risk factors for venous obstruction after implantation of transvenous pacing leads. *Pacing Clin Electrophysiol*, 25: 1605-11.
- Oupadia, P & Ramasswamy, K. (1998). "R-on-T phenomenon" Images in Cardiology. *N Engl J Med*, 338: 1812.
- Res, JCJ; de Priester, JA; van Lier, AA; van Engelen, CLJM; Bronzwaer, PNA; Tan P-H; Visser, M. (2004); Pneumothorax resulting from subclavian puncture: a complication of permanent pacemaker lead implantation. *Neth Heart*, 12: 101-5.
- Rozsmus, G; Daubert, JP; Huang, DT; Rosero, S; Hall, B; Francis, C. (2005). Venous thrombosis and stenosis after implantation of pacemakers and defibrillators. *Pacing Clin Electrophysiol*, 13: 9-19.

- Sohail, MR; Uslan, DZ; Khan, AH et al. (2007). Management and outcome of permanent pacemaker and implantable cardioverter-defibrillator infections. *J Am Coll Cardiol*, 49:1851-9.
- Trohman, RG; Kim, MH; Pinski, SL. (2004) Cardiac pacing: the state of the art. *Lancet*, 364: 1701-19.
- van Eck, JWM; van Hemel, NM; Zuithof P, et al. (2007). Incidence and predictors of in-hospital events after first implantation of pacemakers. *Europace*, 9: 884-9.
- Van Gelder, BM; Bracke, FA; Oto, A; Yildirim, A; Haas, PC; Seger, JJ, et al. (2000). Diagnosis and management of inadvertently placed pacing and ICD leads in the left ventricle: a multicenter experience and review of the literature. *Pacing Clin Electrophysiol*, 23: 877-83.
- Vardas, PE; Auricchio, A; Blanc, JJ et al for the Task Force Members. Guidelines for cardiac pacing and cardiac resynchronisation therapy. (2007). *Europace*, 9: 959-98.
- Wiegand, U.K.; Lejeune, D.; Boguschewski, F.; Bonnemeier, H.; Eberhardt, F.; Schunkert, H.; & Bode, F. (2004). Pocket hematoma after pacemaker or implantable cardioverter defibrillator surgery: influence of patient morbidity, operation strategy, and perioperative antiplatelet/anticoagulation therapy. *Chest*, 126, 1177-86
- Zoll, PM. (1952). Resuscitation of the heart in ventricular standstill by external electric stimulation. *N Engl J Med*, 247: 768.